



Guiding patients to better oral health

Anna Middleton presents a case requiring full-mouth guided biofilm therapy

A 41-year-old male patient booked a hygiene and whitening appointment through direct access.

First, the patient was informed by the dental hygienist about the scope of practice offered by direct access, and he was happy to proceed on the basis that anything outside that capacity would require referral to a dentist.

Despite being an irregular attendee to the dentist/dental hygienist, he presented with a fairly good level of oral health.

Both extraoral and intraoral examinations were carried out, including oral cancer screening and a basic periodontal examination (BPE).

He was assessed to have a score of 000/121 (ie, no pockets >3.5mm, but supragingival or subgingival calculus/overhangs and light bleeding on probing).

There was a lack of interdental cleaning, with bleeding on probing and marginal inflammation, as well as visible plaque and calculus deposits.

On the plus side, he was a non-smoker and, at the time of presenting, his

general health was good.

Guided biofilm therapy

A solution was proposed that would provide the most suitable course of treatment for the patient, based on clinical findings.

This involved a personally tailored oral hygiene routine and full mouth guided biofilm therapy (GBT) with EMS Airflow (using Plus powder and ultrasonic (USS) debridement of the calculus).

Not only would this procedure achieve the desired results, it would also be


minimally invasive and pain-free.

Once everything had been explained to the patient, he gave consent for GBT treatment to go ahead.

A gentle, effective and safe state-of-the-art system, GBT consists of treatment protocols based on a patient's diagnosis and risk assessment.

Game-changing prophylaxis

Following assessment, the patient's full mouth was disclosed. The patient was shown what had been disclosed and then educated on how to manage his



Anna Middleton

Anna is a multi-award-winning dental hygienist. She studied at the Eastman Dental Hospital after working as a dental nurse and graduated in 2015 from the Faculty of Royal College of Surgeons. She is the founder of London Hygienist, which has a mission to change the way oral healthcare is delivered to patients. Anna is a key opinion leader for Philips, a global guided biofilm therapy ambassador for EMS Dental and an ambassador for the BSDHT as well as a member. Anna lectures, and writes regularly for both industry and consumer press. She is currently training to be a dental therapist.



ENHANCED CPD

GDC Development outcomes: C

Topic: Guided biofilm therapy (GBT)

Enhanced CPD hours: 1

Aims and objectives

This article presents a case of GBT.

Anticipated outcomes

Correctly answering the questions on page 49 will show the reader has a clear understanding of using GBT in practice.



The GBT process in eight simple steps

1. Assess

Probe and screen every clinical case:

- Healthy teeth, caries, gingivitis, periodontitis
- Healthy implants, mucositis, peri-implantitis
- Start by rinsing with Bacterx Pro mouthwash.

2. Disclose

Make biofilm visible:

- Highlight to patients the disclosed biofilm and their problematic areas with EMS Biofilm Discloser
- The colour will guide biofilm removal
- Once biofilm is removed, calculus is easier to detect.

3. Motivate

Raise awareness and teach:

- Emphasis on prevention
- Instruct your patients in oral hygiene
- EMS recommends Sonicare toothbrushes and interdental brushes or Airfloss Ultra.

4. Airflow

Remove biofilm, stains and early calculus:

- Use Airflow for natural teeth, restorations and implants
- Remove biofilm supra- and subgingivally up to 4mm using Plus 14µm powder
- Remove remaining stains on enamel

using Classic Comfort Powder

- Also remove biofilm from gingiva, tongue and palate.

5. Perioflow

Remove biofilm in >4-9mm pockets:

- Use Plus Powder on natural teeth in deep pockets and root furcations and on implants
- Use new and slimmer Perioflow nozzle.

6. Piezon PS

Remove remaining calculus:

- Use the minimally invasive EMS PS instrument supra- and subgingivally up to 10mm
- Clean >10mm pockets with mini curette
- Use EMS PI instrument around implants up to 3mm subgingivally and on restorations.

7. Check

Make your patient smile:

- Do a final check for remaining biofilm
- Ensure calculus is fully removed
- Accurately diagnose caries
- Protect with fluoride.

8. Recall

Healthy patient equals happy patient:

- Schedule recall frequency according to risk assessment
- Ask your patient if they liked the treatment.

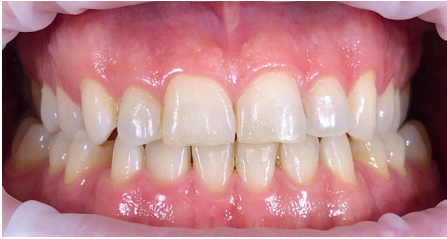

Figure 1: Before guided biofilm therapy

oral hygiene effectively at home.

Full-mouth GBT and full-mouth USS was then performed. This was followed by the application of a fluoride gel to the teeth.

Using GBT rather than more traditional prophylaxis methods (ie, scale and polish) left a good amount of time in the 45-minute appointment to educate the patient about what had been done, why it had been done, and what was needed going forwards.

Tooth whitening options

We also discussed whitening options. The patient was told that a dental hygienist can only perform whitening under the prescription of a dentist and that a check-up would be required.

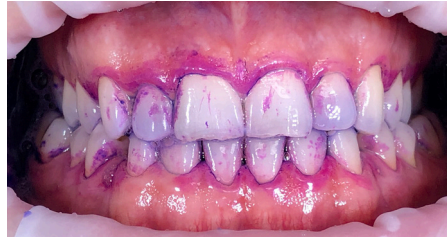

Figure 2: Disclose - the second step of GBT

The patient opted for home whitening and further appointments were made, plus there was enough time in the appointment to take a digital scan of the patient's teeth to send to the lab to fabricate whitening trays.

Looking to the future

Bringing the appointment to an end, the patient was provided with verbal post-treatment instructions and was again advised of his clinical diagnosis of localised gingivitis and the importance of good oral hygiene. This led on to a review of his oral hygiene and personalised home care instructions.

He had been using a manual toothbrush and performed interdental cleaning once a

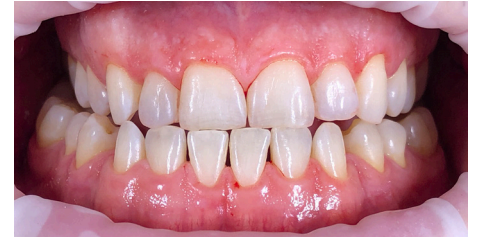

Figure 3: After guided biofilm therapy

week. Instead, he was advised to use an electric toothbrush twice daily, clean between the teeth with interdental brushes and make use of a single-tufted brush.

The patient was also advised to attend at least every six months to maintain his periodontal health. During that appointment, the patient's oral hygiene instructions would be reviewed, and debridement performed as appropriate (ie, another round of GBT). **OH**



For more information about guided biofilm therapy, visit www.ems-dental.com.